IMAGES IN CLINICAL MEDICINE

Stephanie V. Sherman, M.D., *Editor*

Conjunctival Papilloma

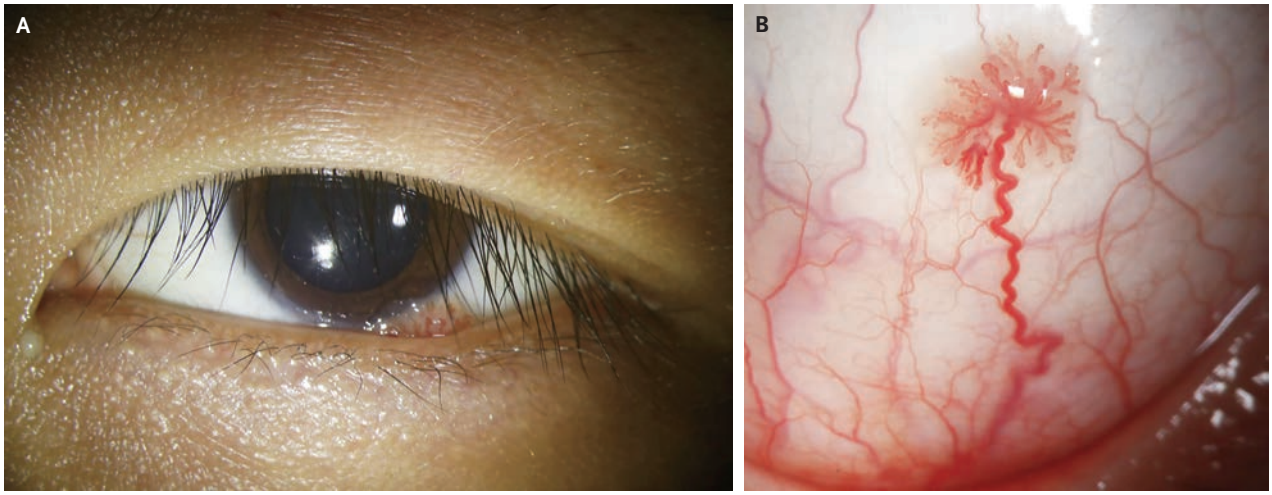

A 26-year-old man presented to the ophthalmology clinic with a 2-month history of a painless, reddish growth on his left eye. A physical examination was notable for the presence of a sessile mass protruding just above the lower eyelid (Panel A). When the eyelid was lowered, the entire mass — including its vascular fronds and episcleral feeder vessel — was visible on the surface of the inferior bulbar conjunctiva (Panel B). Mild conjunctival hyperemia was also present. There were no cutaneous lesions. Surgical excision with cryotherapy was performed. Histopathological evaluation of the specimen revealed hyperplasia of the stratified squamous epithelium with cores of fibrovascular tissue. A diagnosis of conjunctival papilloma was made. Conjunctival papilloma is one of the most common benign tumors of the eye. It most often occurs in young adults and is associated with human papillomavirus, against which this patient had not been vaccinated. Its characteristic appearance as a well-demarcated sessile or exophytic papule with "hairpin" vessel loops helps to differentiate it from malignant lesions. Management options include local therapy with interferon alfa-2b, surgery with cryotherapy, or both. At a 3-month follow-up visit, the lesion had not recurred.

Zehao Liu, B.Med.
Ying Lin, M.D., Ph.D.

Zhongshan Ophthalmic Center of Sun Yat-sen University
Guangzhou, China
liny83@mail.sysu.edu.cn

This article was updated on July 19, 2024, at NEJM.org.

DOI: 10.1056/NEJMicm2401200
Copyright © 2024 Massachusetts Medical Society.

The New England Journal of Medicine is produced by NEJM Group, a division of the Massachusetts Medical Society.
Downloaded from nejm.org on July 23, 2025. For personal use only.
No other uses without permission. Copyright © 2024 Massachusetts Medical Society. All rights reserved.